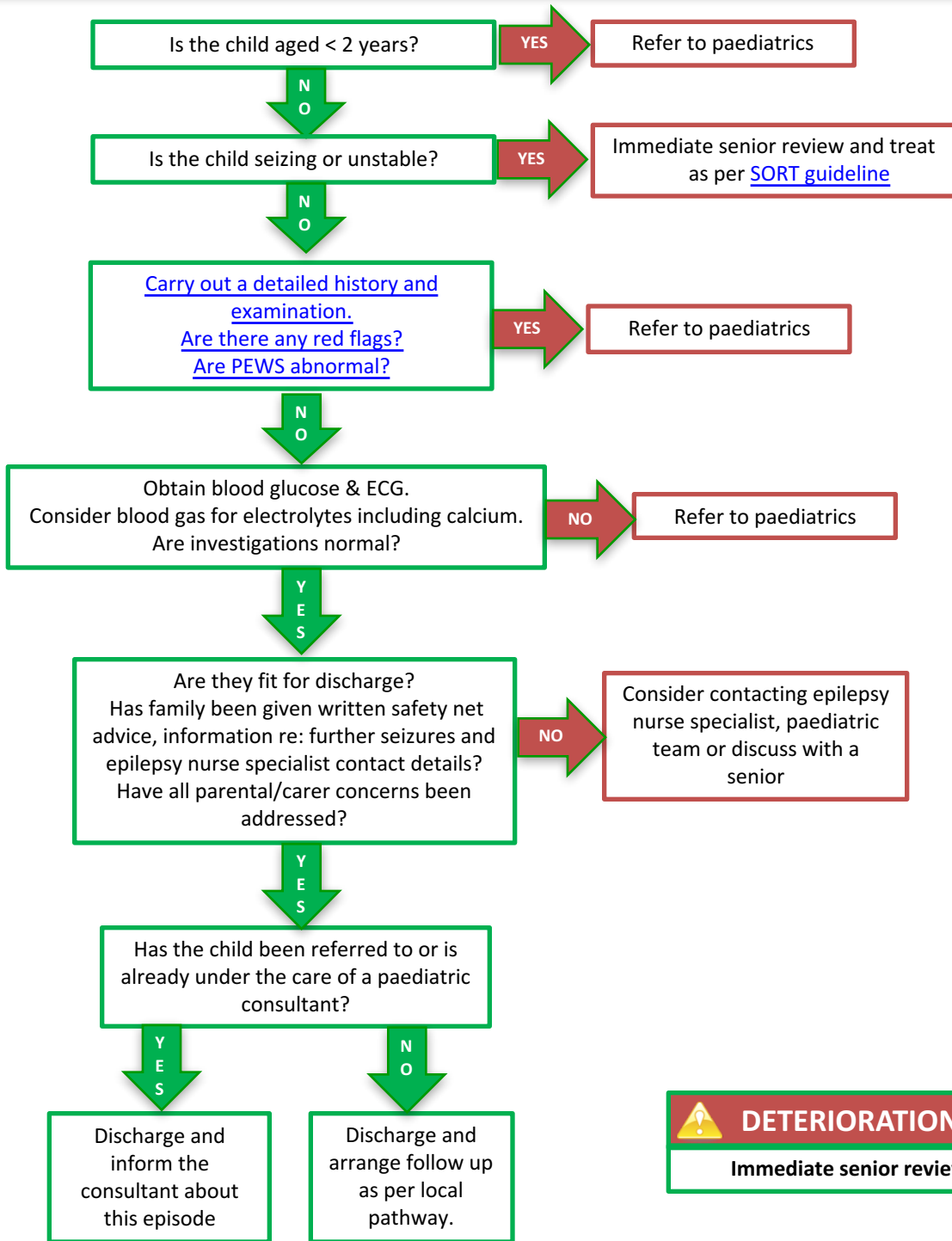


# First Afebrile Seizure



 **DETERIORATION**  
Immediate senior review

History Red Flags
Head injury
Drugs, alcohol or toxin ingestion
Prolonged seizure > 10 mins
Focal seizure
Developmental delay or regression
Required > 1 dose benzodiazepine
Immunosuppressed
Bleeding disorder
Any concurrent illnesses
Any safeguarding concerns

Examination Red Flags
Systemically unwell
Reduced GCS
Not fully recovered
Focal neurological signs
Signs of raised ICP
Signs of meningism
Abnormal cardiac examination
Signs suggestive of non-accidental injury

Important points on history
What happened before, during & after the event – from child and eye witnesses. Ask 'What happened first' - and get a clear chronology of events.
How long did it last
Were they unresponsive
Any movements / focality/ colour change
Any dizziness, visual disturbances, palpitations, painful stimuli
Is there any previous history of similar episodes? Ask specifically about absences, myoclonic jerks and nocturnal seizures
Any family history of cardiac conditions or sudden death in young people
Any family history of epilepsy
Any concurrent illnesses or fever
Any safeguarding concerns