Nutcracker Syndrome

Dr Heena Kithany
Specialty Registrar
Dorset County Hospitals NHS Trust

Case 1: JB

- Referred at 17.9yrs with intermittent abdominal pain and few episodes of painless frank haematuria
- Past medical history: Eczema, Asthma
- Brother had dilated left kidney at birth otherwise nil significant family history
- Examination: Normal
- BP slightly elevated, normal urinalysis
- AXR/USS KUB: NAD
- Investigations: UPCR:5.8, Autoimmune screen, Anti DNAse B, ANA, ANCA- Normal

Case 1: JB

- Month later: CT scan done after d/w Radiologist about the possibility of NCS: There was *approximately 50% narrowing of the left renal vein between the SMA and the aorta and reduction of the SMA aortic angle with the SMA lying near parallel with the aorta at the level of the left renal vein* suggestive of Nutcracker syndrome
- Transferred to adult services
- December 2016: seen by Adult Nephro Team
- Normal examination
- Bloods/Urine NAD/BP borderline elevated

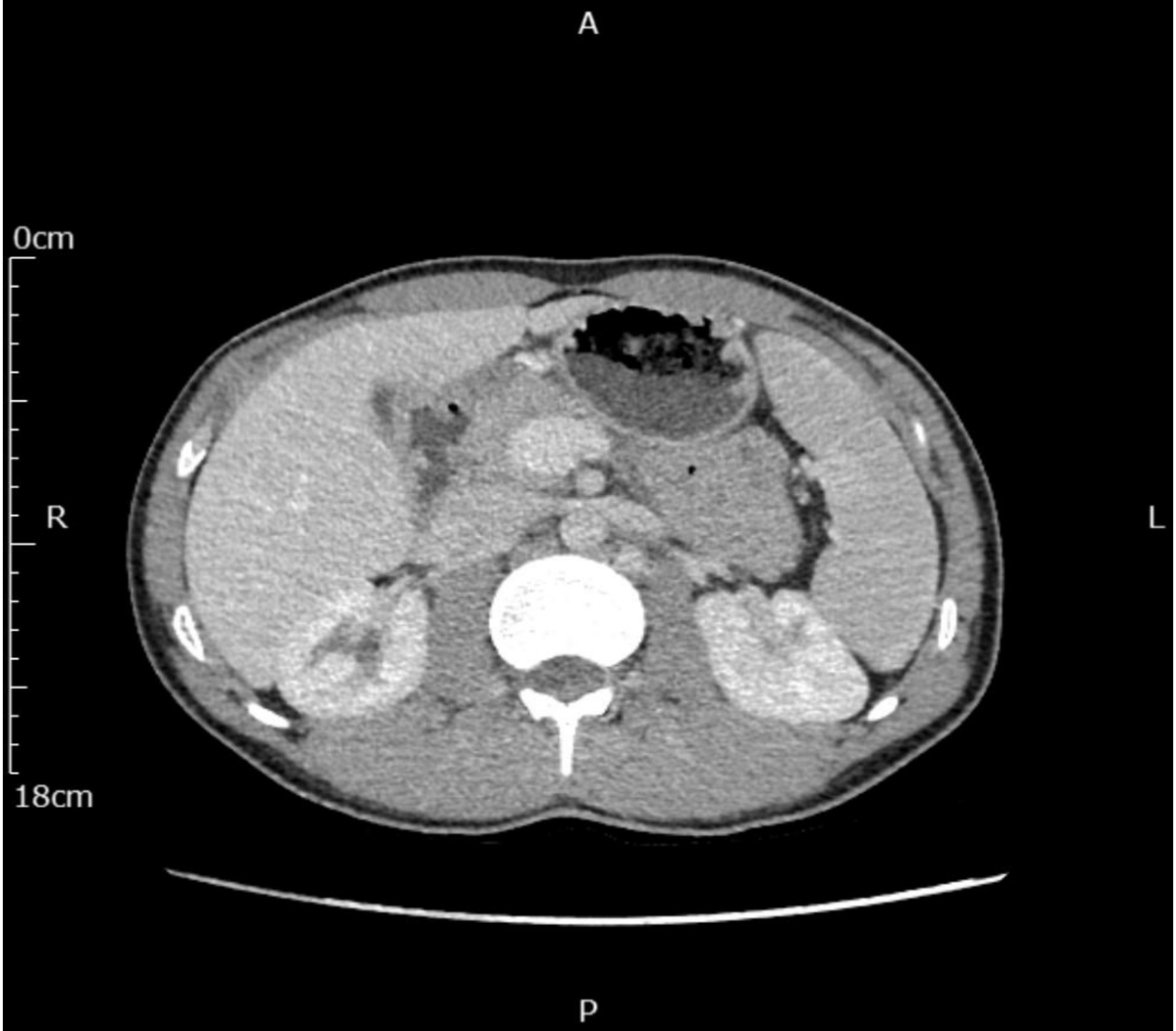
A
0cm
R
L
18cm
P

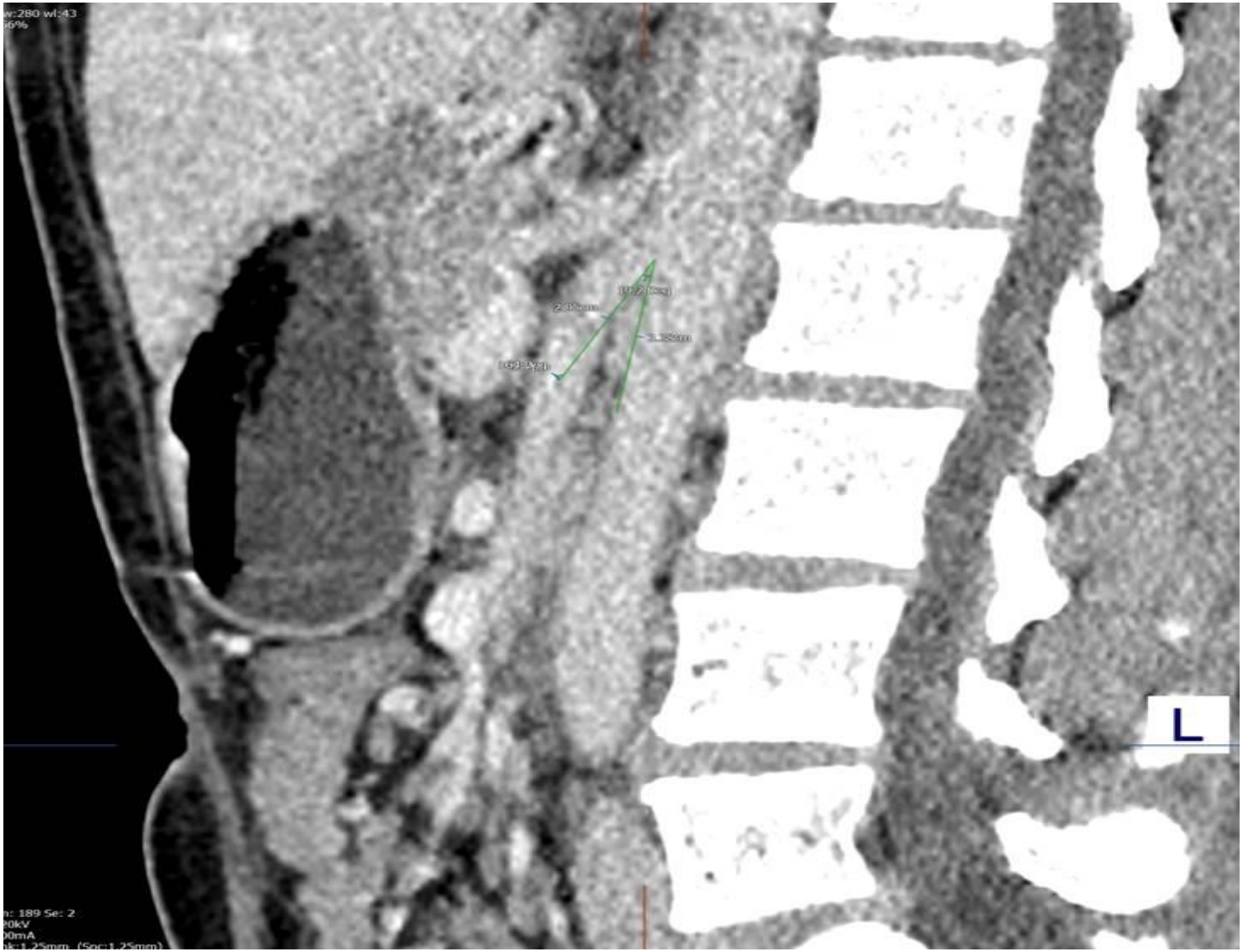
L

Case 1: JB

- Conservative Management
- Weight gain to increase intra-abdominal fat between SMA and Aorta
- ?Stenting of Left renal vein, gonadal vein transposition if ongoing pain
- Followed up: Feb 2017
- Conservative management
- Borderline BP (145/82mm Hg), under monitoring
- Normal bloods and urine

Case 2 BL

- Seen at 15yrs of age with painless frank haematuria and left renal angle pain
- Initially treated as UTI(culture negative)
- No improvement of symptoms, PMH: Asthma
- Initial Referral:
- Normal bloods: UPCR slightly elevated, complement, Anti DNase, ANCA, ASOT, Urinary electrolytes, Immunoglobulins, Urine Cyteine/Oxalate
- BP/USS KUB NAD

- Reviewed week later:
- Ongoing pain and Frank haematuria
- Examination: ongoing left renal angle tenderness, Normal BP
- Urine +Blood, Proteinuria 3+
- UPCR raised slightly
- D/W Radiology about CT scan ? NCS

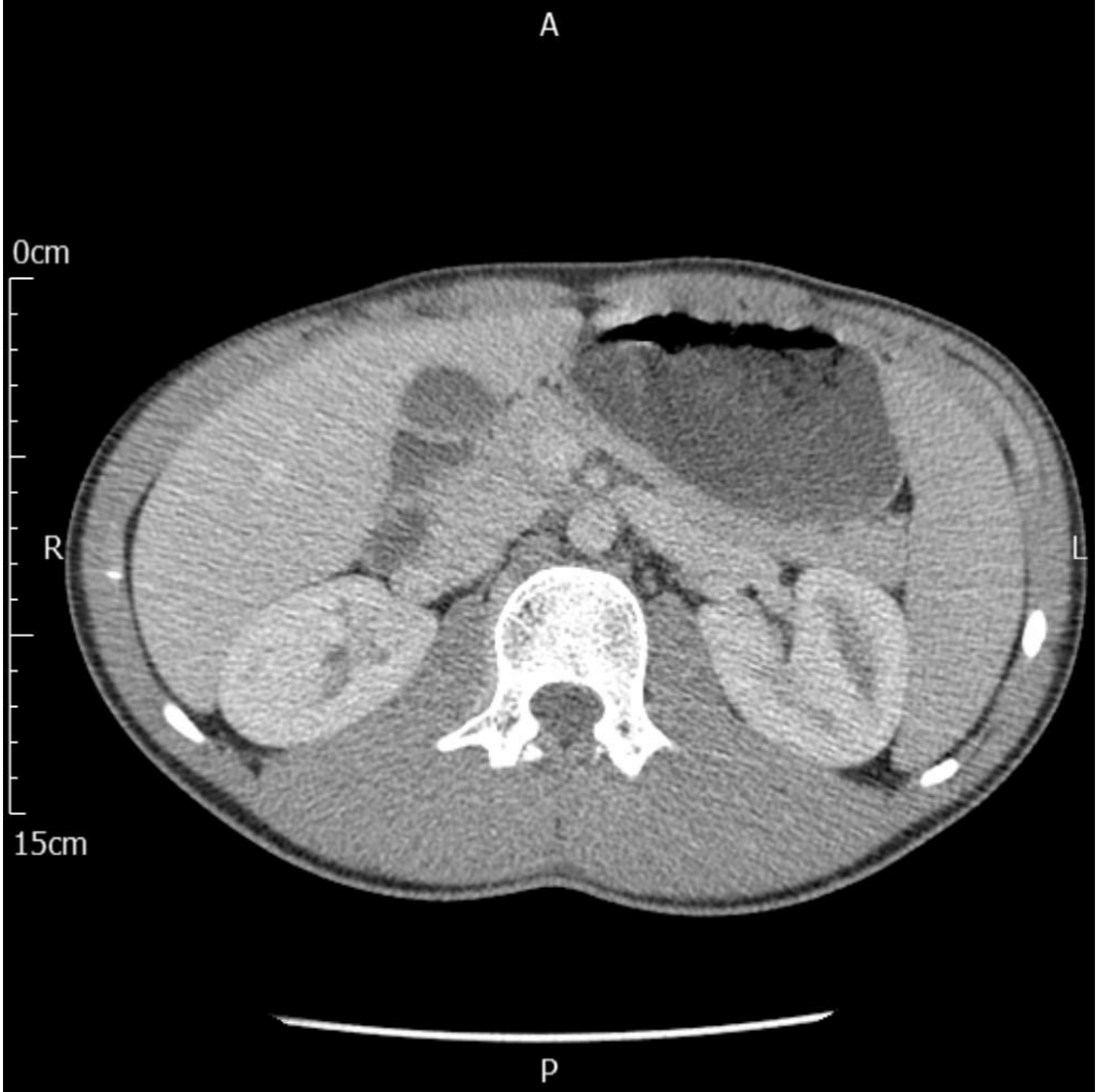
A
0cm
R
L
15cm
P

Case 2 BL

- CT scan: *evidence of compression of the proximal dilated left renal vein between the superior mesenteric artery and aorta due to an abnormal acute SMA-aortic angle/nutcracker syndrome*
- Management: Conservative
- D/W Paediatric Urology:

  - Advised conservative Mx

Case 2 BL

- Ongoing Pain and acute admission 6 months later with severe pain
- BP: normal, Repeat USS KUB- NAD
- Required fentanly PCA
- D/W Anaesthetist/Local Pain team lead: Fentanyl patch and oxycodone prn
- d/w Paed Urology at SGH
- Plan: Continue conservative management, if requires surgical Mx/Stenting would need referral to Evelina

Case 2 BL

- Referred to Transplant Team at Evelina
- Also developed left scrotal pain/Lump
- Diagnosed: likely venous congestion secondary to NCS, conservative management
- October 2015: Seen by Evelina: Under investigation and view to operate to resolve renal vein compression
- F/U in 6/12: March 2016 : For Abdominal MRA


A
0cm
R
L
18cm
P

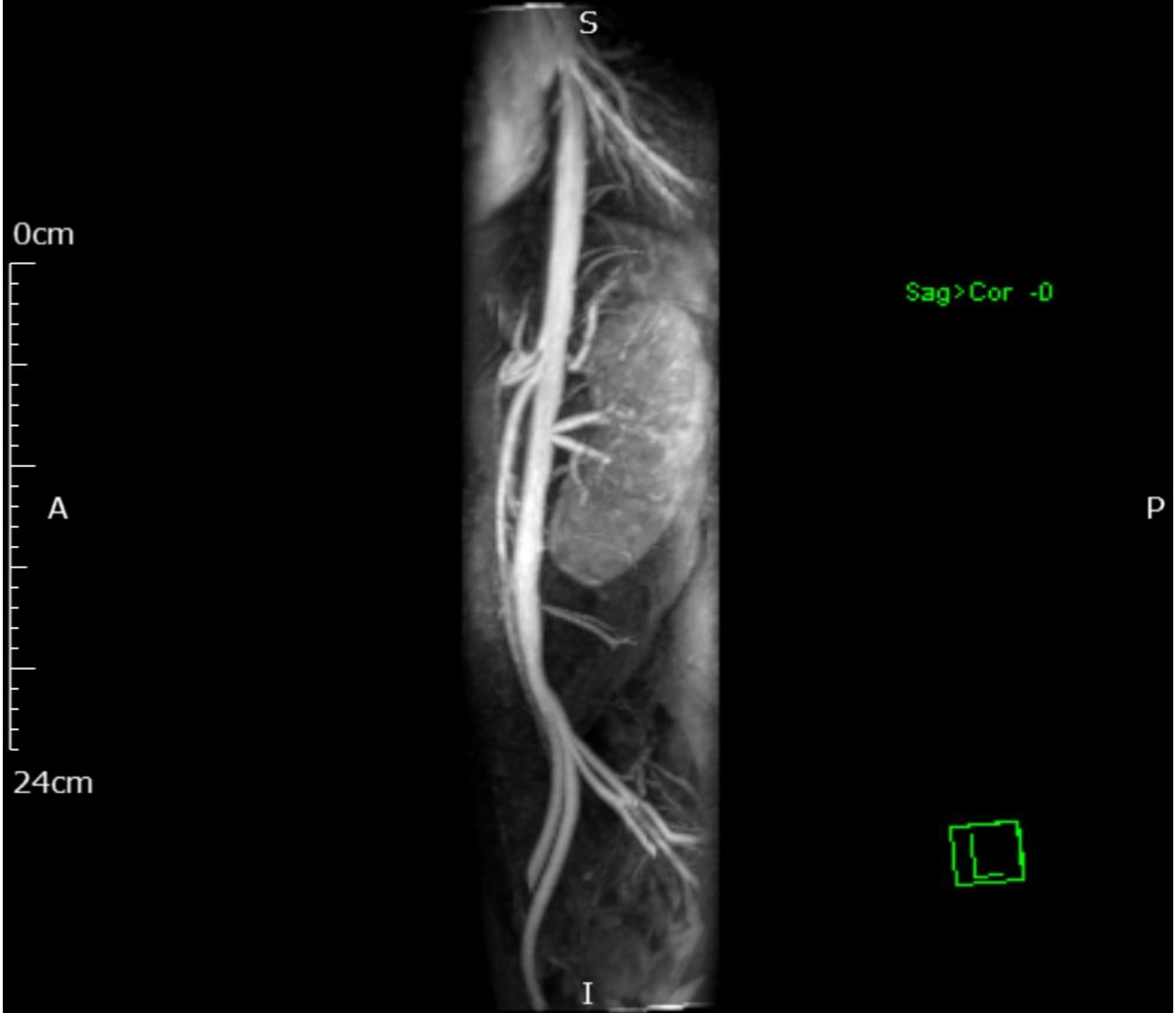
S
0cm
Sag>Cor -0
A
P
24cm
I

Case 2 BL

- June 2016:
- Renal MRA : The MRI confirms the left-sided Nutcracker syndrome
- Both kidneys are normal in size shape

- Plan: For Kidney Transplant ‘front to back’ October 2017

Nutcracker Syndrome

- The nutcracker syndrome (NCS)—is a manifest variant of nutcracker phenomenon, renal vein entrapment syndrome, or mesoaortic compression of the left renal vein
- Results most commonly from compression of left renal vein between the abdominal aorta(AA) and superior mesentric artery (SMA)
- Leads to renal venous hypertension, resulting in rupture of thin-walled veins into the collecting system with resultant haematuria

Nutcracker Syndrome

- The name derives from the fact that, in the sagittal plane and/or transverse plane ,the SMA and AA (with some imagination) appear to be a nutcracker crushing a nut (the renal vein)
- Frequently results in delayed or incorrect diagnosis
- Some cases of mild NCS in children may be due to changes in body proportions associated with growth

Signs and Symptoms

- Frank Hematuria – can lead to anaemia
- Abdominal pain-classically left flank or pelvic pain
- Left testicular pain in men or left lower quadrant pain in women: Since the left gonad drains via the left renal vein
- Nausea/vomiting due to compression of splanchnic veins
- Unusual manifestation: varicocele / varicose veins in lower limbs

Following increases the risk of developing NCS due to compression of the left renal vein:

- Pancreatic/retroperitoneal Tumors
- Swelling of para aortic lymph nodes
- Abdominal Aorta Aneursym

Diagnosis

Radiological

- Gold Standard test: Left renal venography
- CT Scan
- Abdominal USG—not definitive

Radiographic features:

- Reduced aortic-SMA angle (the normal aorta and SMA angle is approximately 45(38-65)
- left renal vein stenosis
- collateral pathways: mainly the left gonadal vein
- pressure gradient >3 mm Hg on renal venography

Differential Diagnosis

1)Superior Mesenteric Artery Syndrome (Wilkie Syndrome)/Also called as SMA compression disorder

- SMA compresses the third part of duodenum

2)May–Thurner and Cockett syndrome also known as the iliac vein compression syndrome: (present with extensive DVT of venous disease of the leg, these usually respond to stenting)

Complications of disease:

- Renal Vein Thrombosis
- Renal failure
- Aneamia secondary to haematuria

Treatment

Depends on the severity and symptoms:

- Conservative: Analgesia/Adequate Hydration

- Surgical:

- Endovascular stenting
- Renal vein re-implantation
- Gonadal vein embolization

Prognosis

- Usual course not clear
- remains under-diagnosed as symptoms vary from person to person
- Some cases, more commonly in children, can resolve spontaneously
- without treatment, predisposes to left renal vein thrombosis and kidney damage

Prognosis

- surgically with open repair: good long-term outcomes
- less-invasive endovascular stent: good results in the short term but have a risk of migration

Thank you

Questions?